

PREDICTABLE SYNTHETIC BONE GRAFTING PROCEDURES FOR IMPLANT RECONSTRUCTION: PART TWO

*Scott D. Ganz, DMD
Maurice Valen*

KEY WORDS

**Synthetic bioactive
Bone regeneration
Resorbable graft
Ridge preservation
Osteoconductive
Implant placement**

Scott D. Ganz, DMD, is clinical attending at Hackensack University Medical Center, assistant clinical professor at University of Medicine and Dentistry of New Jersey, faculty and guest lecturer of numerous implant preceptorship programs nationally and internationally, and maintains a private maxillofacial prosthodontic specialty practice at 158 Linwood Plaza, Suite 204, Fort Lee, NJ 07024.

Maurice Valen is the president and director of research and development of Impladent Ltd; adjunct assistant professor, Department of Dental and Materials Science; and lecturer on restorative and prosthodontic sciences, New York University, College of Dentistry. Address correspondence to Mr Valen at Impladent Ltd, 198-45 Foothill Avenue, Holliswood, NY 11423.

When teeth are missing, the surrounding bone and soft tissue is challenged as a result of the natural resorptive process or from traumatic destruction subsequent to extraction. The diminished structural foundation for prosthetic reconstruction with or without implants can therefore be compromised. Recent technological innovations in computer hardware and software have given clinicians the tools to determine 3-dimensional anatomy, quality, and density of bone, which can aid in the diagnosis and treatment planning for reparative or augmentative grafting procedures. Advanced synthetic bioactive resorbable bone graft (SBRG) materials and innovative surgical techniques have made it possible to predictably alter the defective site to create favorable osseous conditions for implant placement. The synthetically derived, resorbable, cluster-like, hydrophilic, particulate, bone-grafting material, having similar mechanical and chemical properties as the host bone, can provide the means to modify existing bone topography by aggressively overpacking the material for ridge preservation, ridge augmentation, or to enhance the bony site and subsequent prosthetic rehabilitation. Since bone does not bridge in empty spaces, the aggressive overfill, commonly referred to as force mineralization, controls excessive bleeding and eliminates voids. Part 1 of this 2-part series presented evidence of safety and effectiveness of the SBRG materials, crystal morphology, chemical properties, and characterization through animal and clinical studies. The osteoconductive cluster particulate assists in the bridging of lost bone anatomy by chemotactic response and resorption concurrent with regeneration of new bone formations. Part 2 demonstrates specific clinical handling characteristics and use of this material to facilitate implant placement and/or prosthetic reconstruction through clinical case applications. Additionally, in a unique clinical presentation, a composite graft mixture consisting of the SBRG and dense, ceramic, bovine-derived HA (sintered at 1150°C) was compared using electron microscopy.

INTRODUCTION

Bone grafting has become a valuable, mainstream clinical procedure that can be utilized in a variety of reconstructive applications and as a desired precursor for implant placement. Ridge preservation after tooth extraction can be important to maintain edentulous areas for later denture support, fixed bridge applications, or implant reconstruction. It has become routine for onlay grafts and combination bone grafts to be utilized as predictable treatment alternatives to restore form and function of lost or resorbed bone.^{1,2} Various formulations and materials have been developed to provide clinicians with bone substitutes that can be used to enhance new bone formation or to serve as a bioactive resorbable foundation for the new bone to grow.³⁻⁵ A variety of biologically and synthetically derived bone augmentation materials have been used as mixtures for the therapeutic repair and restoration of osseous defect sites, post-tooth extraction, prior to and during implant placement, periodontal reconstruction, sinus augmentation procedures, and cyst-removal sites. This material has given clinicians the ability to offer patients alternative treatment modalities that can serve to restore missing bone anatomy for ridge maintenance or preservation, ridge augmentation, and for enhanced bone foundation for endosseous implant placement.⁶⁻⁸

CASE PRESENTATIONS

Four clinical cases were chosen to represent several different clinical examples that illustrate the efficacy of particulate bone grafts, and specifically the use of a synthetic bioactive resorbable graft (SBRG) of low-temperature HA material (OsteoGen, Implants Ltd, Holliswood, NY). In each case the existing bone topography was modified through the application and use of particulate bone graft materials in dif-

ferent anatomical regions and with different implant types.

Case study 1: anterior mandible

A 72-year-old man presented with a poor periodontal prognosis for the 4 mandibular incisors. After a careful evaluation of the radiographic and clinical presentation, several treatment alternatives were proposed. The patient desired a fixed replacement for the anterior segment; however, the resulting postextraction defect would create a long span that would require multiple terminal abutments for adequate support. Therefore it was elected that the teeth would be extracted and 3 endosseous root-form cylinder implants would be immediately placed to help preserve the ridge and support a fixed-detachable prosthesis. Under local anesthetic agent, a full-thickness mucoperiosteal flap was elevated to expose the buccal and lingual aspects of the 4 incisors with releasing incisions extending bilaterally. The periodontal compromised teeth were elevated and removed without difficulty. The residual alveolar ridge and crestal bone was leveled to remove thin buccal and lingual bone spicules and to create adequate width for fixture placement. The autogenous bone was collected and kept in sterile saline for later use in the graft mixture.

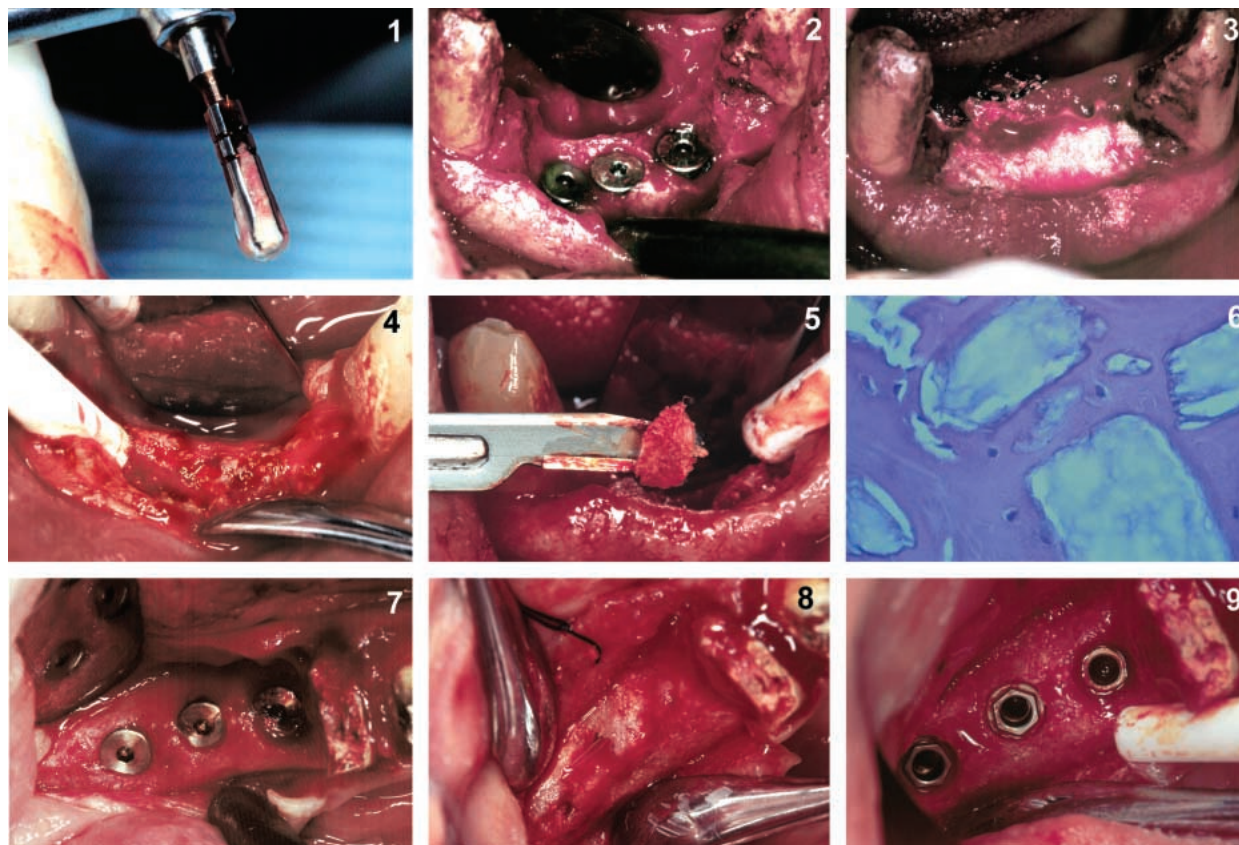
Three osteotomies were prepared using sequential drills under internal and external irrigation according to the manufacturer's guidelines. Bone coagulum was collected from within the flutes of the drills during the preparation and carefully placed into sterile saline with previously harvested bone (Figure 1). Three implants were then placed slightly below the alveolar crestal bone (Figure 2). A graft mixture consisting of harvested autogenous bone combined with SBRG was placed into a wide syringe, expressed, and compacted onto the site covering the implants, filling any voids. Clinically, SBRG is very hydrophilic and light by nature. Accordingly, the material must be compacted extremely well to avoid

excess spaces (force mineralization). Since bone does not bridge in space, excessive water or bleeding must be controlled for a well organized bone restoration (Figure 3). Primary closure was achieved and healing was unremarkable. The implants were allowed to integrate for 4 months, at which time the site was re-entered with a modified full-thickness mucoperiosteal flap. The underlying implants were found to be covered with a thick layer of mature bone (Figure 4). A sharp, No. 15 scalpel blade was used to carefully remove sections of bone until the implant cover screws were reached approximately 2 mm inferior to the new crest (Figure 5). This bone was preserved for later histological sectioning and examination.

The histological section revealed mature bone surrounding the remaining crystals of bioactive resorbable particulates (Figure 6). The Haematoxylin and eosin-stained photomicrograph revealed well-organized new bone formation in direct apposition to the SBRG crystals and with no intervening soft tissue. It can be determined that the osteocytes within the lacunae (Figure 6, arrows) denote mature bone formation. Concentric layering of lamellae were noted at the left-hand corner. The alveolar ridge was significantly augmented in both height and width, resulting in an increased volume to support the soft tissue, which would later be draped around the healing collars subsequently placed onto each implant. The increased volume of bone is important for both the long-term success of the individual fixtures, soft tissue response, and hygienic maintenance of the prosthesis.

Case study 2: posterior mandible

A 67-year-old man presented with a long-standing posterior edentulous right-mandible ridge. The remaining mandibular right first molar had been hemisected, having required the extraction of the distal root. The patient desired a fixed-type reconstruction to rebuild the posterior occlusion. With-



FIGURES 1-9. FIGURE 1. Bone coagulum collected from within the flutes of the drills. FIGURE 2. Three implants placed slightly below the alveolar crestal bone. FIGURE 3. The graft mixture consisting of harvested autogenous bone combined with a synthetic bioactive resorbable particulate expressed onto the site and packed aggressively. FIGURE 4. Re-entering the surgical site found the underlying implants covered with a thick layer of mature bone. FIGURE 5. A sharp No. 15 scalpel blade was used to carefully remove the layer of new bone over the implants. FIGURE 6. The histological section revealed mature bone surrounding remaining crystals of bioactive resorbable particulates. FIGURE 7. Osteotomies were carefully prepared to receive 3 press-fit, root-form implants. FIGURE 8. After 4 months, the implant site was re-entered and found completely covered with a thick new layer of mature bone. FIGURE 9. A sharp scalpel again was used to remove and bevel bone for healing collars.

out natural tooth posterior abutments, the only source of support for fixed restorations would be endosseous implants. After a review of the necessary radiographs, clinical examination, and mounted study casts to determine vertical dimension and occlusal scheme, it was elected to place 3 root-form-type implants. One fixture planned to replace the distal root of the first molar, and 2 additional implants were treatment-planned for additional posterior support.

A full-thickness mucoperiosteal flap was elevated to expose the underlying alveolar ridge. Utilizing both internal and external irrigation, osteotomies were carefully prepared to receive 3 press-fit, root-form implants, which were placed without incident (Figure

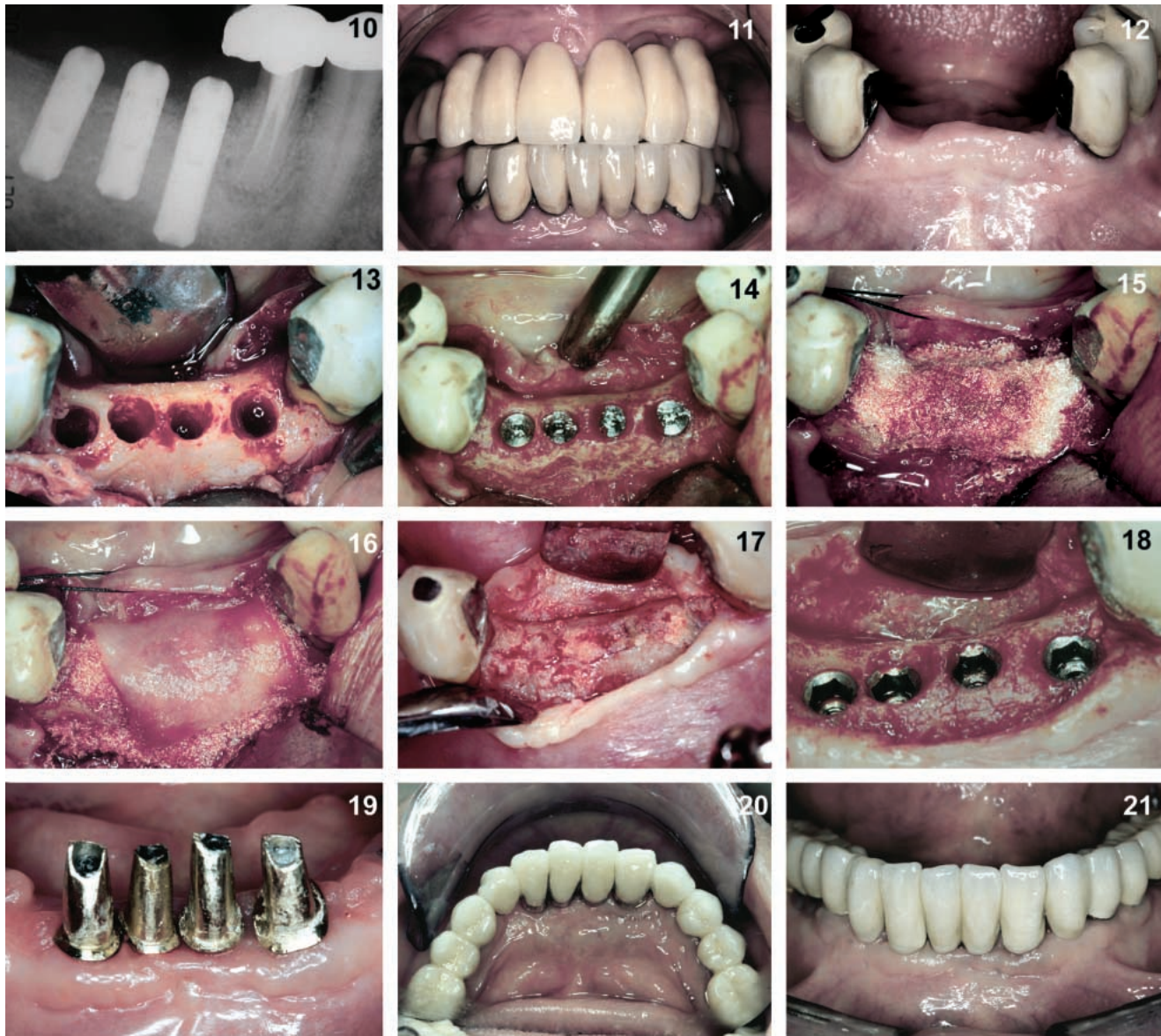
7). As previously described, bone was collected from each site and mixed with the SBRG. This bone graft mixture was placed and compacted over the site and subsequently covered with a resorbable collagen membrane (CollaCote, Sulzer-Dental, Carlsbad, Calif). Primary closure was achieved, and healing was unremarkable.

After 4 months, the implant site was re-entered. The implants were found to be completely covered with a thick new layer of mature bone (Figure 8). Samples of the bone were collected for later histological examination. A sharp scalpel was used to expose the implants and bevel the bone to conform to the flare and diameter of the healing collars to ensure proper seating without interference from the bony over-

growth (Figure 9). The healing collars were placed and a verification radiograph was taken to check the fit (Figure 10). The prosthetic reconstruction continued with impressions, prepared stock abutments, and the fabrication of a cementable fixed bridge to re-establish posterior occlusion. This case has been in function for over 6 years while maintaining the height and width of the supporting bone.

Case study 3: posterior mandible

A 68-year-old man presented with a failing mandibular, anterior, fixed bridge that supported a lower bilateral semiprecision partial denture (Figure 11). Radiographic examination revealed an abundance of bone in the anterior region and sufficient height and



FIGURES 10–21. FIGURE 10. The healing collars were placed and a verification radiograph was taken to check the fit. FIGURE 11. A 68-year-old man presented with a failing mandibular anterior fixed bridge supporting a lower bilateral semiprecision partial denture. FIGURE 12. Under local anesthetic agent, the bridge was sectioned exposing the severely resorbed alveolar ridge. FIGURE 13. Four osteotomies were prepared in the anterior mandible under copious irrigation. FIGURE 14. Four 3.3-mm Screw-Vent implants were carefully placed slightly below the lingual crest, leaving some of the screw threads exposed on the buccal aspect. FIGURE 15. Previously harvested autogenous bone mixed with the synthetic bioactive resorbable graft and compacted over the site. FIGURE 16. The translucent porous collagen membrane placed over the bone graft absorbs surrounding red blood cells. FIGURE 17. After osseointegration occurred, a full-thickness flap was utilized to expose the underlying bone, which fully covered all implants. FIGURE 18. Each implant was carefully exposed and the thickness of the regenerated ridge was apparent. The bone was beveled for healing collar attachment. FIGURE 19. Four separate custom cast gold alloy posts were fabricated. FIGURE 20. The occlusal view reveals the natural appearance and morphology recreated in the ceramo-metal restoration. FIGURE 21. The facial view exhibits the natural appearance that was of paramount importance to this patient.

width of bone in the anterior region for implant placement. Further examination of CT scan data revealed good bone quality and favorable bone topography to proceed with implant placement. The only area that was found to be deficient in bone volume and bone

width was the mandibular incisor region, which was previously restored with a long-span, fixed bridge containing 4 anterior pontics. The patient desired a full-arch fixed restoration, which would be accomplished simultaneously with a similar treatment

plan for the maxilla. Additionally, the patient wished to maintain normal size, morphology, and aesthetics for the lower teeth to look as natural as possible.

After careful review of the 3-dimensional topography provided by the CT

scan, 11 potential sites were predetermined. Implants were planned in staggered sequence to allow the patient to maintain his removable partial denture during the healing process. The first stage was to section the existing fixed bridge and place 4 implants anteriorly. Under local anesthetic agent, the bridge was sectioned exposing the severely resorbed alveolar ridge (Figure 12). New acrylic teeth were then laboratory processed to the existing partial denture for later use. A full-thickness mucoperiosteal flap was raised to reveal the underlying bony crest. Under copious internal and external irrigation, 4 osteotomies were prepared (Figure 13). Although difficult to distinguish from the illustration, the lingual cortical bone was approximately 3 to 4 mm higher than the resorbed buccal plate. No effort was made to flatten this ridge. As previously described, bone was again harvested and collected from the drill flutes and placed in a stainless steel dish with sterile saline solution. The osteotomies were prepared at the height of the lingual plate, leaving a discrepancy or void because of the lost buccal wall. Four 3.3-mm Screw-Vent implants (Sulzer Dental, Carlsbad, Calif) were carefully placed slightly below the lingual crest, leaving some of the screw threads exposed on the buccal aspect (Figure 14).

The previously harvested autogenous bone from the osteotomy preparations was mixed with SBRG delivered to the site and compacted to increase density (Figure 15). After sufficient graft material was added to fill the defect, a resorbable collagen membrane covered the site (CollaCote, Sulzer Dental, Carlsbad, Calif). Red blood cells were first absorbed around the edges of the translucent, porous membrane (Figure 16). It is postulated that the retention of the blood clot by the resorbable membrane will act as a nutrient base to the underlying graft. The soft tissue flaps were then approximated, and primary closure was achieved. Healing was monitored without incident for 4 months. After os-

seointegration had occurred, a full-thickness flap was used to expose the underlying bone (Figure 17). Successful augmentation of the ridge was achieved in the buccal-lingual dimension as well as in the vertical dimension, as illustrated once the soft tissue was fully reflected. The vertical bony overgrowth required the use of a sharp scalpel to carefully section off the thick layer of bone that covered the implants. Each implant was carefully exposed and the bone beveled slightly to accept the flair of the transmucosal healing abutment. This beveling of the bone and the thickness of the regenerated ridge is apparent in Figure 18. The staged placement of posterior implants was accomplished after the anterior implants were uncovered. The remaining implants were placed in a similar manner to that previously described.

After a short healing period, impressions were taken for this anterior area, and 4 separate custom cast gold alloy posts were fabricated (Figure 19). The final ceramometal restoration was completed according to standard prosthodontic protocol. An occlusal view revealed the natural appearance and morphology recreated in the porcelain (Figure 20). The synthetic, non-ceramic, bioactive bone grafting and augmentation procedure enabled the proper amount of soft tissue support to keep the vertical height of the anterior teeth to within normal and aesthetic limits. Proper embrasures and adequate keratinized gingival tissue allowed the patient to maintain good long-term hygiene maintenance provided by a well organized osseous structure. The facial view exhibits a natural appearance, which was of paramount importance to this patient (Figure 21).

DISCUSSION

In general, particulate bone grafts are not used to fixate implants, but rather to enhance thin bone trabeculation and "force mineralize" large marrow spacings. This technique provides initial bulk supported by a resorbable bioac-

tive material that in time turns in to bone. Dependent on defect size, human biopsies collected for the past 15 years have demonstrated resorption at different time intervals and chemotactic control of connective tissue migration. On the average, the results show that 80% of the material will resorb some time by the fourth or sixth month, depending on patient's metabolic state, age, and defect size and vascularity. This resorption mechanism is also dependent on the amount of material delivered (ie, 0.25 vs 1 g), and most importantly, the area of vascularity where the material was implanted. For example, 0.25 g for periodontal application may resorb in 4 months, whereas 6 g for a sinus elevation may take 9 months to resorb.⁹⁻¹⁵

Grafting with SBRG helps to maintain or recreate favorable contours of the bone at the ridge crest or buccal plate, which in turn helps support the overlying soft tissue that is important for long-term maintenance and aesthetic excellence. When utilizing the techniques illustrated, it is recommended that a full-thickness mucoperiosteal flap be used to re-enter an implant or grafted site. As shown in this study, the graft material has matured and completely covers previously placed implants. The preservation or augmentation of the ridge helps preserve and maintain the bone and soft tissue architecture, which is important for the prosthetic phase as well as in the long-term hygienic maintenance of the site. Lost buccal cortical plate and large defects can be regenerated, enhancing the treatment options available for our patients.

CONCLUSIONS

Reconstructive dentistry has evolved to include replacement or augmentation of lost anatomical structures such as teeth, gingival tissue, and bone. Volumetric changes in the hard and soft tissues as a result of tooth loss, infection, or trauma can adversely affect the clinician's ability to properly restore form and function. Innovative surgical tech-

niques have been developed to predictably restore lost structures. Cluster-like particulate of SBRG material has demonstrated to be an effective modality to repair and/or augment bony defects to facilitate prosthetic reconstruction supported by endosseous implants.¹⁶ In addition to augmentation of bone, necessary support for keratinized soft tissue is also achieved as an adjunct for aesthetic concerns and long-term hygienic maintenance of the definitive prosthesis. In recent extraction sites or areas where bone has been lost, short- and long-term success has been demonstrated in both parts 1 and 2 of this 2-part series. Mature bone growth was substantiated and confirmed through histological evaluation. Additionally, a difference was demonstrated between an SBRG, which has the benefit of similar chemical and mechanical properties as natural bone, vs densely structured filler material, which often fibro-encapsulates and migrates.

Low-temperature SBRG, having an osteoconductive chemotactic response similar to the dissolution rate of the host bone, provides an excellent foundation for implant placement. Because of the material's chemical potentiality, and by virtue of its physico-chemical characteristics similar to bone mineral and potential ability to resorb over time and be replaced by bone, this material is an attractive bone substitute material, especially when packed aggressively as a grouting intermediary with or without titanium implants. By promoting mineralization of the compromised physiologic interface, the surgical site is provided with initial implant support. Implant concavities or dehiscence walls where screw threads are exposed can be grouted, forming a bridging mechanism for new bone support and regeneration. Particulate bone

grafting techniques have been demonstrated to be a viable treatment modality that should be considered when there is a need to replace lost bone in a variety of clinical presentations. Clinicians should be aware that particulate bone graft material can be used to enhance site preparation for implant placement and support for soft tissue morphology which benefits the ultimate prosthetic reconstruction.

REFERENCES

1. Ganz SD. Restoring the anterior maxillary arch with an implant supported fixed bridge. *Implant Soc.* 1993;4:2-5.
2. Ganz SD. Replacing four mandibular incisors with an implant supported prosthesis. *Implant Soc.* 1993;4:2-9.
3. Valen M, Ganz SD. A synthetic bioactive resorbable graft for predictable implant reconstruction: part one. *J Oral Implantol* 2002;28:167-177.
4. Epstein SR, Valen M. An alternative treatment of the periodontal infra-bony defect: a synthetic bioactive resorbable composite graft. *J Periodontol.* In press.
5. Listrom RD, Symington JM. Osseointegrated dental implants in conjunction with bone grafts. *Int J Oral Maxillofac Surg.* 1988;17:116-118.
6. Vlassis JM, Hurzeler MB, Quiñones CR. Sinus lift augmentation to facilitate placement of nonsubmerged implants: a clinical and histological report. *Pract Periodont Aesthetic Dent.* 1993;5:15-23.
7. Duncan JM, Westwood RM. Ridge widening for the thin maxilla: a clinical report. *Int J Oral Maxillofac Implants.* 1997;12:224-227.
8. Quiñones CR, Casellas JC, Caffesse RG. Guided periodontal tissue regeneration (GPTR): an update. *Pract Periodont Aesthetic Dent.* 1996;8:169-180.
9. Ricci JL, Blumenthal NC, Spivak JM, Alexander H. Evaluation of a low-temperature calcium phosphate particulate implant material: physical-chemical properties and in vivo bone response. *J Oral Maxillofac Surg.* 1992;50:969-978.
10. Spivak JM, Ricci JL, Blumenthal NC, Alexander H. A new canine model to evaluate the biological response of intramedullary bone to implant materials and surfaces. *J Biomed Mat Res.* 1990;24:1121-1149.
11. Quiñones CR. Treatment of gingival recession using guided periodontal tissue regeneration. *Pract Periodont Aesthetic Dent.* 1997;9:145-154.
12. Corsair A. A clinical evaluation of resorbable hydroxylapatite for the repair of human intra-osseous defects. *J Oral Implantol.* 1990;16:125-128.
13. Wagner JR. A clinical and histological case study using resorbable hydroxylapatite for the repair of osseous defects prior to endosseous implant surgery. *J Oral Implantol.* 1989;15:186-192.
14. Wagner JR. A 3½-year clinical evaluation of resorbable hydroxylapatite OsteoGen (HA Resorb) used for sinus lift augmentations in conjunction with the insertion of endosseous implants. *J Oral Implantol.* 1991;17:152-164.
15. Whittaker JM, James RA, Lozada J, Cordova C, GaRey DJ. Histological response and clinical evaluation of heterograft and allograft materials in the elevation of the maxillary sinus for the preparation of endosteal dental implants sites. Simultaneous sinus elevation and root form implantation: an eight-month autopsy report. *J Oral Implantol.* 1989;15:141-144.
16. Ganz SD. Mandibular tori as a source for onlay bone graft augmentation. A surgical technique. *Pract Periodont Aesthetic Dent.* 1997;9:973-984.